











## Pituitary *pars intermedia* dysfunction in horses associated to pituitary adenoma<sup>1</sup>

Anderson H. Gris<sup>2\*</sup> , Ronaldo M. Bianchi<sup>2</sup> , Claiton I. Schwertz<sup>2</sup> ,  
Manoela M. Piva<sup>2</sup> , Gabriela Richter<sup>3</sup> , Luciana Sonne<sup>2</sup> ,  
David Driemeier<sup>2</sup>  and Saulo P. Pavarini<sup>2</sup> 

**ABSTRACT.**- Gris A.H., Bianchi R.M., Schwertz C.I., Piva M.M., Richter G., Sonne L., Driemeier D. & Pavarini S.P. 2023. **Pituitary *pars intermedia* dysfunction in horses associated to pituitary adenoma.** *Pesquisa Veterinária Brasileira* 43:e07117, 2023. Setor de Patologia Veterinária, Faculdade de Veterinária, Universidade Federal do Rio Grande do Sul, Av. Bento Gonçalves 9090, Porto Alegre, RS 91540-000, Brazil. E-mail: [anderson\\_gris@hotmail.com.br](mailto:anderson_gris@hotmail.com.br)

The clinical syndrome of the pituitary *pars intermedia* dysfunction (PPID) is the most common endocrinopathy of older horses. This syndrome is characterized by several clinical and pathological changes, which are usually associated with adenomas of the *pars intermedia* (PI) of the pituitary gland. The aim of this work is to describe five cases of pituitary adenoma of the PI associated with PPID in horses, addressing its clinical and pathological aspects. The horses had a mean of 22 years of age. The main clinical signs were hirsutism and paresis of hind limbs, and at *post mortem* examination all horses had hirsutism, and a nodule in the pituitary gland, which was histologically characterized as an adenoma of PI (5/5). Furthermore, two horses had gross lesions suggestive of chronic laminitis. Moreover, there was intense parasitism of *Sarcocystis neurona* (2/5), *Strongylus vulgaris* (1/5), *Parascaris equorum* (1/5), *Draschia megastoma* (1/5), and *Klossiella equi* (1/5).

INDEX TERMS: PPID, hypothalamus, parasitism, hirsutism, laminitis, horses, equine.

**RESUMO.**- [Disfunção da *pars intermedia* da hipófise em equinos associado a adenoma pituitário.] A síndrome clínica da disfunção da *pars intermedia* da hipófise (PPID) é a endocrinopatia mais comum em cavalos idosos. Essa síndrome é caracterizada por várias alterações clínicas e patológicas, geralmente associadas a adenomas da *pars intermedia* (PI) da hipófise. O objetivo deste trabalho é descrever cinco casos de adenoma hipofisário de PI associado a PPID em equinos, abordando seus aspectos clínicos e patológicos. Os cavalos apresentaram média de 22 anos de idade. Os principais sinais clínicos incluíam hirsutismo e paresia dos membros pélvicos, e no exame *post mortem* todos os equinos apresentavam hirsutismo e um nódulo na glândula pituitária, que foi histologicamente caracterizada como um adenoma de PI (5/5). Além disso, dois cavalos tinham lesões macroscópicas sugestivas de laminite crônica. Ainda, havia

intenso parasitismo de *Sarcocystis neurona* (2/5), *Strongylus vulgaris* (1/5), *Parascaris equorum* (1/5), *Draschia megastoma* (1/5) e *Klossiella equi* (1/5).

TERMOS DE INDEXAÇÃO: PPID, hipotálamo, parasitismo, hirsutismo, laminite, equinos.

### INTRODUCTION

The clinical syndrome of the pituitary *pars intermedia* dysfunction (PPID) is the most common endocrinopathy of aged horses (Leitenbacher & Herbach 2016, Rosol & Gröne 2016). The pathogenesis of the condition in horses is believed to be related to the loss of the dopaminergic inhibition due to a neurodegenerative lesion caused by the aging (Fortin et al. 2020). These lesion leads to an excessive production of pro-opiomelanocortin (POMC) in the PI and its derivatives, followed to hypertrophy, hyperplasia, or adenomas of PI. These nodules can extend beyond the *sella turcica* and compress the hypothalamus, which impair its function (McFarlane et al. 2003, McFarlane 2011, Spelta 2015, Miller et al. 2016, Rosol & Gröne 2016).

Clinical signs of horses with PPID are variable, but the most common are hirsutism, polyphagia, chronic laminitis, weight

<sup>1</sup> Received on August 18, 2022.

Accepted for publication on September 8, 2022.

<sup>2</sup> Setor de Patologia Veterinária, Faculdade de Veterinária (FAVET), Universidade Federal do Rio Grande do Sul (UFRGS), Av. Bento Gonçalves 9090, Porto Alegre, RS 91540-000, Brazil. \*Corresponding author: [anderson\\_gris@hotmail.com.br](mailto:anderson_gris@hotmail.com.br)

<sup>3</sup> Centro Universitário Ritter dos Reis (UniRitter), Av. Manoel Elias 2001, Alto Petrópolis, Porto Alegre, RS 91240-261, Brazil.

loss, hyperpyrexia, hyperhidrosis, abnormal distribution of adipose tissue, increased susceptibility to secondary infections, diabetes insipidus, as well as a lethargic and docile behavior. These clinical findings are mainly due to a hypothalamic or neurohypophyseal dysfunction caused by the compressive nodules (Miller et al. 2016, Rosol & Gröne 2016). This work aims to describe five cases of pituitary adenoma of the PI associated with PPID in horses, addressing its clinical and pathological aspects.

## MATERIALS AND METHODS

A retrospective study of the *post mortem* examination database of the Department of Veterinary Pathology (DVP) of the “Universidade Federal do Rio Grande do Sul” (UFRGS) was conducted, by electronic research using the keywords “adenoma”, “hypofisis” and “*pars intermedia*”, to search for cases of PPID from January 2012 to December 2019. Information available in the submission forms and pathology reports was retrieved. Moreover, the gross pictures and the histological slides were reviewed at optical microscopy to provide detailed gross and histologic description.

In the *post mortem* examination, samples of all organs were collected, fixed in 10% formalin, routinely processed for histology, and stained by hematoxylin and eosin (HE). In cases with lesions compatible with equine protozoal myeloencephalitis (EPM), the histological slides were submitted to immunohistochemistry anti-*Sarcocystis neurona*, as described by Henker et al. (2020) employing a primary polyclonal antibodies anti-*S. neurona* (1:200 in phosphate-buffered saline – PBS). Antigen retrieval was obtained with proteinase K for 1 minute, and secondary MACH 4 Universal HRP-Polymer (Biocare, Pacheco/CA, USA) were used. The reactions were revealed with 3,3'-diaminobenzidine chromogen (DAB, Dako, Carpinteria/CA, USA). Slides from known cases of EPM were used as positive controls, and primary antibodies were replaced by irrelevant polyclonal antibody for negative control.

## RESULTS

From January 2012 to December 2019, 449 *post mortem* examinations were performed in horses, five of which (1.11%, cases 1-5) were diagnosed as PPID associated with adenoma of the PI. All horses were from Rio Grande do Sul state, Southern Brazil (Table 1).

A clinical diagnosis of PPID was made in all cases by the clinical signs (Table 1), however, in Horse 3, the field veterinarian additionally performed a dexamethasone suppression test for clinical confirmation of PPID. Before dexamethasone application, serum cortisol levels were of 133nmol/L (reference value (RV): 50-225nmol/L), while 12 hours after dexamethasone administration, the value was of 162.5nmol/L (RV: <25nmol/L).

Grossly, all horses had excessively long, thick, and wavy hair (hirsutism) (Fig.1); while Horses 2, 3 and 5 were also in poor body condition, with marked loss of muscle mass, and Horses 2 and 3 had still lesions on the hoofs suggestive of chronic laminitis. Additionally, the pituitary gland of all horses was markedly enlarged, round, and measured from two to three centimeters in diameter. On the cut surface, all pituitary glands showed increase in volume, expanding and compressing the glandular parenchyma. These nodules were soft, multilobulated, and white to light brown, with multifocal interspersed dark red areas (Fig.2). These masses compressed the *pars distalis* (PD) and *pars nervosa* (PN) to the rostral and caudal margin of the gland. Also, the tumor moved dorsally through the *sella turcica* and compressed the overlying hypothalamus.

Horse 1 had free gastric content in the abdominal cavity due to the rupture of the stomach. Parasitism by nematodes was detected in two horses; Horse 3 had large amounts of nematodes within small intestine morphologically compatible with *Parascaris equorum*. Horse 5 had a yellowish nodule inside the cranial mesenteric artery, friable and contained nematodes with morphology compatible with *Strongylus vulgaris*. In addition to that, the gastric wall was thickened

**Table 1. Identification, clinical history, and cause of death of the five horses with PPID syndrome**

| Case    | Breed         | Sex/Age         | History and clinical features  | Cause of death  |
|---------|---------------|-----------------|--|---|
| Horse 1 | Crioulo       | Female/26 years | Hirsutism, polyphagia and colic signs, submitted to exploratory laparotomy, showing gastric and intestinal distention, which was reduced in surgery. However, the horse did not recover.   | Gastric rupture   |
| Horse 2 | Anglo Arabian | Female/30 years | Hirsutism for a year, polyphagia, laminitis treatment for three weeks, and after that, started to present generalized loss of muscle mass, tetraparesis, ataxia, nystagmus, hypothermia, progressive weakness and progressed to lateral decubitus. | Euthanasia due to neurologic signs (presumably to equine protozoal myeloencephalitis) |
| Horse 3 | Crioulo       | Male/20 years   | Hirsutism, polyphagia, and muscle loss during a year. The last month before the euthanasia, the horse showed incoordination of hind limbs, that progressed to paresis, blindness, and decubitus.   | Euthanasia due to neurologic signs (presumably to equine protozoal myeloencephalitis) |
| Horse 4 | Thoroughbred  | Female/18 years | Hirsutism, polyphagia, and hyperhidrosis for a year before the euthanasia. A week before the death it starts to present incoordination, circling walk and emaciation.  | Euthanasia due to neurologic signs  |
| Horse 5 | Mixed breed   | Female/16 years | Hirsutism without time history and was found in decubitus two days before the euthanasia, as it did not recover. Also presented polyphagia.  | Euthanasia due to decubitus and poor prognosis  |

PPID = pituitary *pars intermedia* dysfunction.



by elevated multifocal mucosal nodules of 1cm in diameter, which were associated with *Draschia megastoma*.

Histologically, the pituitary gland of all horses had a neoplastic proliferation of well differentiated epithelial cells in the PI, which were multilobulated, partially encapsulated and delimited, and almost completely replaced the pituitary parenchyma and compressed the PD and PN (Fig.3). The neoplastic cells were arranged in cords or nests separated by a fine septa of fibrovascular stroma. The cells were round to polyhedral, with granular eosinophilic cytoplasm and slightly evident borders. The nucleus was round to oval, consisting of granular chromatin with an evident nucleolus. Anisocytosis and anisokaryosis were moderate, and rare mitotic figures were observed. Frequently the neoplastic cells also assumed a second pattern of pseudorosettes, characterized by elongated cells arranged in palisade around blood vessels (Fig.4). Occasionally, follicular structures were formed, being full of dense eosinophilic material in the center. Moreover, there was proliferation of blood vessels and cavities full of blood cells. In the skin of three horses, the hair follicles were predominantly in anagen phase and moderate multifocal parakeratotic hyperkeratosis were also observed.

In the central nervous system of the Horses 2 and 3 parasitism by *S. neurona* (EPM) was observed, and the lesions were in the region of pons and medulla oblongata, which were characterized by multifocal areas of encephalomalacia with inflammatory infiltrate of macrophages, eosinophils and in minor number, lymphocytes, especially surrounding blood vessels (perivascular cuffing). Also, associated to the lesion, there were several intralesional protozoans morphologically compatible with schizonts and merozoites of *S. neurona* (Fig.5). Both cases were submitted to immunohistochemistry (IHC), which revealed strong immunolabeling for *S. neurona* (Fig.5 inset).

Moreover, Horse 3 also had *Klossiella equi* infection, in which protozoans were detected within the tubular epithelium of the kidneys. Also, there was mild multifocal

interstitial inflammatory infiltrate of lymphocytes, Mott cells, macrophages, and multinucleated giant cells (Fig.6). Near the parasitized cells, there were occasional areas of rupture and loss of tubular epithelium.

In the gastric mucosa of Horse 5 had a moderate eosinophilic and lymphoplasmacytic inflammatory infiltrate with sections of nematodes with morphology consistent with *Draschia megastoma*. Also, in the intima layer of the mesenteric artery had a neutrophilic inflammatory infiltrate associated with sections of nematode with histological features compatible with *Strongylus vulgaris*.

## DISCUSSION AND CONCLUSION

In the current study, the diagnosis of PPID was based on the association of clinical and pathological findings, and the frequency of this condition in the necropsied horses of the selected period was low (1.11%), which corroborates with another study that had a rate of 0.2% (Rohrbach et al. 2012). However, the frequency is usually higher in clinical studies, ranging from 2.9% to 8% of all the diagnosis in horses (Brosnahan & Paradis 2003, Welsh et al. 2016). The different frequency of PPID in pathological and clinical studies may be explained by the classic clinical presentation of this condition, which is easily recognized in the clinical practice, thus necropsy is usually not performed in such cases.

The mean age in this study (22 years) was similar to that described by other authors, in which PPID is usually observed in horses older than 15 years old (Rohrbach et al. 2012, Spelta 2015, Leitenbacher & Herbach 2016, Rosol & Gröne 2016). Some reports describe a higher frequency of this condition in mares (Spelta 2015, Leitenbacher & Herbach 2016, Rosol & Gröne 2016), and one survey describes no sexual predisposition to develop pituitary adenomas or PPID (Miller et al. 2016). In this work, it was not possible to infer any sexual predisposition to PPID in horses due to the small number of cases.

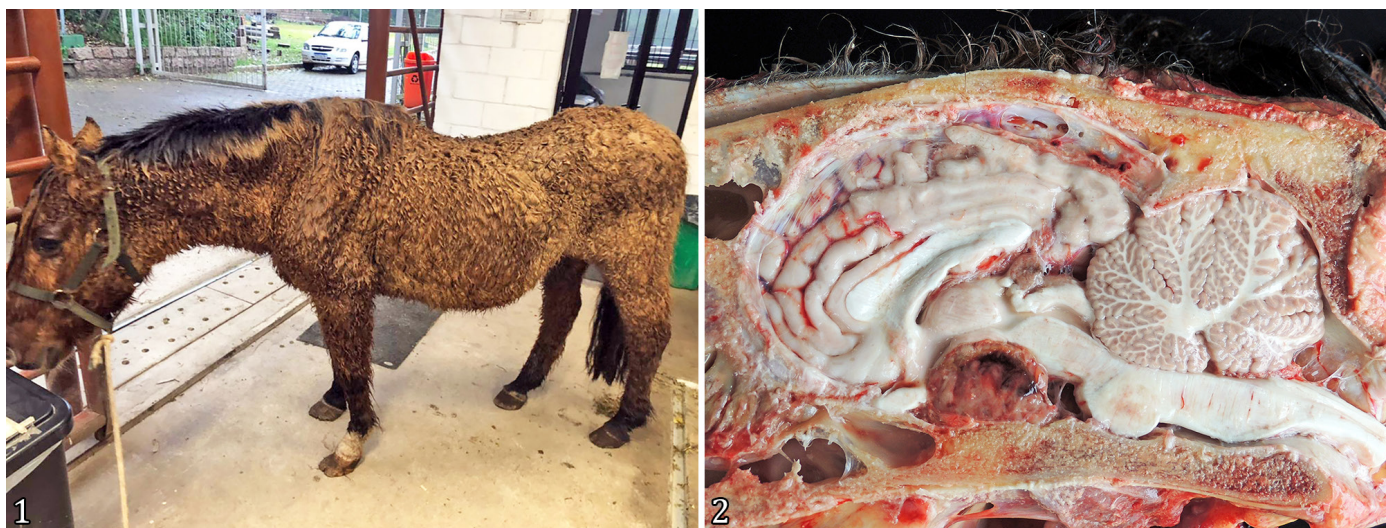

Fig.1-2. Macroscopic findings of horses with pituitary *pars intermedia* dysfunction (PPID). (1) Horse 3 with excessively long, thick, and wavy hair and poorly body condition, with marked loss of muscle mass. (2) Head, cut surface (Horse 3). Pituitary gland markedly enlarged, showing a white to light brown mass, with multifocal interspersed dark red areas compressing the glandular parenchyma and the overlying hypothalamus.



The clinical signs of hirsutism and polyphagia were observed in all horses in this study, and they are characteristic of this syndrome (McFarlane 2011, Spelta 2015). The hirsutism lesion was histologically characterized by normal hair follicles predominantly in the anagen phase (active hair shaft production). These changes occur due to the failure of the seasonal shedding of hair, which is performed by the hypothalamus, and leads to constant hair growth and consequent hirsutism (Spelta 2015, Rosol & Gröne 2016). Nonetheless, in murine and minks some studies suggest that the adrenocorticotrophic hormone (ACTH) induces the anagen phase of the hair cycle (Paus et al. 1994, Rose 1998). If this mechanism is also applicable to

horses, the overproduction of POMC and consequent high levels of ACTH in horses with PPID, may also explain the clinical sign of hirsutism. However, no studies have proven this association and further investigation is necessary to confirm this hypothesis.

In humans, it is already known that the neurons in the paraventricular hypothalamic nucleus control the sympathetic outflow to peripheral organs and secrete regulatory neuropeptides. Therefore, damaged neurons of this region lose the inhibitory control of food intake, which leads to overeating (Timper & Brüning 2017). This nucleus is in the hypothalamus, which is often compressed by the pituitary masses in horses with

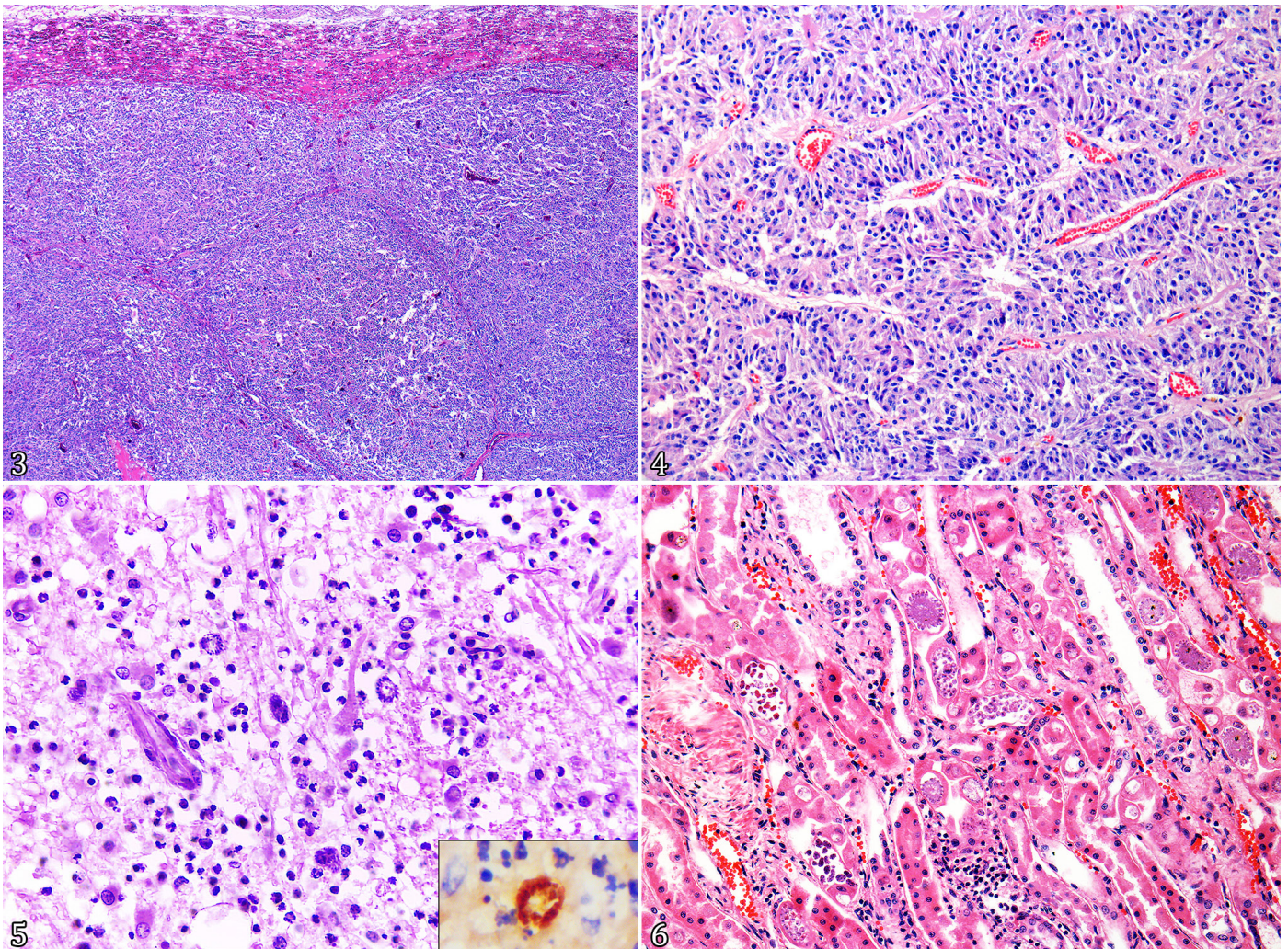


Fig.3-6. Histological findings of horses with pituitary *pars intermedia* dysfunction (PPID). (3) Pituitary gland (Horse 3). A multilobulated, partially encapsulated and delimited neoplastic proliferation of well differentiated epithelial cells of *pars intermedia*, almost completely replaces the pituitary parenchyma and compresses *pars distalis* and *pars nervosa*. HE, obj.4x. (4) Pituitary gland (Horse 3). The neoplastic cells are arranged in cords or nests separated by fine septa of fibrovascular stroma. These cells were polyhedral and frequently assumed a pseudorosette form around blood vessels. HE, obj.20x. (5) Brain (pons, Horse 3). Area of severe necrosis, associated with a severe inflammatory infiltrate of neutrophils, lymphocytes, macrophages, and occasional eosinophils, in addition to substantial amounts of parasitic structures morphologically compatible with schizonts and merozoites of *Sarcocystis neurona*. HE, obj.40x. Inset: There is marked immunolabeling of the parasitic structure. Anti-*S. neurona*. IHC, obj.60x. (6) Kidney (Horse 3). Parasitic structures of *Klossiella equi* in the tubular epithelium, characterized by rounded light basophilic sporonts of 80 to 150µm, with multiple round and basophilic dots of 10µm and disposed in a radiated pattern (sporoblasts). There are oval-shaped amphophilic structures of 10 to 20µm with abundant basophilic dots compatible with mature sporocysts with sporoblasts. There is also mild multifocal interstitial inflammatory infiltrate of lymphocytes, plasma cells and macrophages. HE, obj.20x.



PPID due to incomplete superior diaphragm of the *sella turcica*. This may result in local necrosis, and consequently polyphagia (Rosol & Gröne 2016).

Gastric rupture related death in horses with PPID may be associated with polyphagia, polydipsia, and substantial amounts of  $\beta$ -endorphin ( $\beta$ -END) from the degradation of POMC, which causes a decrease in sensitivity to painful mechanical stimulus, such as gastric distension, and may result in the organ rupture (Millington et al. 1988). Although polydipsia was not reported in our cases, it may have gone unnoticed by the owners. The increase of water consumption in horses with PPID is not as severe as seen in other conditions, therefore it may be underestimated (Schott 2002). Polyuria and polydipsia may occur in horses with PPID due to compression of supraoptic and paraventricular nucleus (partial neurogenic diabetes insipidus) with disturbance of the antidiuretic hormone (ADH) production, as well as the osmotic diuresis associated to glucosuria (McKenzie 2007).

The neurological signs of lateral decubitus, incoordination, tetraparesis, ataxia, nystagmus, blindness, circling walk, and emaciation observed in this study, were also described in 21.2% of clinically assessed horses (Ireland & McGowan 2018). In most cases, the signs are associated with encephalic compression by the adenoma (McFarlane 2011). However, in Horses 2 and 3 of this study, besides the adenoma with secondary compression, an encephalomyelitis associated to *Sarcocystis neurona* was also detected. In these cases, the neurologic signs may have started due to PPID, but worsening of clinical condition with onset of EPM clinical signs were the reason for euthanasia. The condition PPID have a poor prognosis and leads to spontaneous death or euthanasia (Miller et al. 2016), in addition to predispose to potentially fatal secondary infectious diseases, as observed in cases of EPM of this study.

Histologically, in cases of EPM it is often difficult to detect intralesional parasites (Henker et al. 2020); however, in Horse 3, a large number of parasites were observed, which was considered unusual. The authors believe that this may have occurred due to the immunosuppression caused by the elevated levels of endogenous anti-inflammatory hormones, which impaired the host response to the parasite and facilitated its reproduction. Immunosuppression has been considered a predisposition factor for this condition, especially in stressful moments such as injury, surgery, and parturition (Cooley et al. 2007).

Elevated levels of anti-inflammatory hormones, such as  $\beta$ -END, ACTH and  $\alpha$ -melanocyte stimulating hormones ( $\alpha$ -MSH) are caused by the overproduction of POMC by the pituitary gland and may compromise the immune system (Robson et al. 2003, Zak et al. 2020). This fact could justify the several parasitic infections observed in the horses of this study. Similar parasitic infections in immunocompromised horses have been described in previous studies, which reported *S. neurona* and *Klossiella equi* infections in horses with PPID (Jorgensen et al. 2005, Ballweber et al. 2012). *K. equi* is a parasite rarely described in Brazil, and it is usually considered an incidental finding on histopathological exam (Fortes et al. 2017). *Parascaris equorum*, *Drashia megastoma*, and *Strongylus vulgaris* are nematodes sporadically detected in necropsies of horses in Southern Brazil; however, to our knowledge, these multiple parasitic infections have not been

previously associated with older horses with PPID. Additionally, *P. equorum* infections are usually observed only in foals and yearling horses, as they usually develop resistance after six months of age (Hautala et al. 2019).

The gold standard test to clinically diagnose PPID in initial stages remains unknown; however, some tests can be used, such as the dosage of serum PI-derived peptides (corticotropin-like intermediate lobe peptide - CLIP,  $\alpha$ - and  $\beta$ -MSH, and  $\beta$ -END), which may be 40 times higher than normal serum levels (Rosol & Meuten 2017). Other tests that can be performed include dexamethasone suppression, thyrotropin-releasing hormone stimulation, domperidone response, and ACTH stimulation. All these tests should be interpreted cautiously because the horses exhibit higher levels of serum  $\alpha$ -MSH in the autumn, and the serum ACTH may be normal in horses with PPID (McFarlane 2011).

Elevated serum cortisol level of Horse 3 can be associated with PPID due to the increase of the production of POMC with secondary overproduction of ACTH. Since the PI does not respond to the negative feedback by the glucocorticoids, this hormone production is unaffected, and cortisol levels may get higher (McFarlane 2011). However, this situation is not common, as the ACTH produced by PI is less biologically active than the ACTH of PD, therefore the serum cortisol levels usually do not increase as the ACTH (Morgan et al. 2018).

PPID clinical syndrome in horses should not be called Cushing's syndrome, which is observed in dogs, cats, and humans, because it has a distinct pathogenesis. The Cushing's syndrome is the result of a disorder among the hypothalamic-pituitary-adrenal axis control of the corticotrophs and it is mostly associated with an ACTH-secreting adenoma of the PD of the pituitary gland (Rosol & Gröne 2016). PPID has been associated with a hypothalamic and neurohypophyseal derangement as well as an autonomous overproduction of POMC-derived peptides. Additionally, PPID is a primary-related neurodegenerative disease that disturbs the dopaminergic inhibition in the hypothalamic neurons that innervate the PI. Moreover, these neurons do not respond to the glucocorticoids, as PD does (McGowan et al. 2013, Miller 2017).

**Acknowledgements.**- Financial support was supplied by "Conselho Nacional de Desenvolvimento Científico e Tecnológico" (CNPq), "Coordenação de Aperfeiçoamento de Pessoal de Nível Superior" (CAPES) - Finance code 001, "Fundação de Amparo à Pesquisa do Rio Grande do Sul" (FAPERGS), and "Pró-reitoria de Pesquisa da Universidade Federal do Rio Grande do Sul" (Propesq/UFRGS).

**Conflict of interest statement.**- The authors declare having no conflicts of interest.

## REFERENCES

- Ballweber L.R., Dailey D. & Landolt G. 2012. *Klossiella equi* infection in an immunosuppressed horse: evidence of long-term infection. Case Rep. Vet. Med. 2012(1):1-4. <<https://dx.doi.org/10.1155/2012/230398>>
- Brosnahan M.M. & Paradis M.R. 2003. Assessment of clinical characteristics, management practices, and activities of geriatric horses. J. Am. Vet. Med. Assoc. 223(1):99-103. <<https://dx.doi.org/10.2460/javma.2003.223.99>> <PMid:12839072>
- Cooley A.J., Barr B. & Rejmanek D. 2007. *Sarcocystis neurona* encephalitis in a dog. Vet. Pathol. 44(6):956-961. <<https://dx.doi.org/10.1354/vp.44-6-956>> <PMid:18039914>

- Fortes B.N.A., Silva L.F., Moreira M., Spasiani J.P., Sant'anna F.J.F. & Medeiros J.T. 2017. Nefrite intersticial linfoplasmocítica associada à *Klossiella equi* em equino. (IV CBPV, Brasília, DF). Savannah J. Res. Develop. 1(Supl.1):299. (Resumo)
- Fortin J.S., Benskey M.J., Lookingland K.J., Patterson J.S., Howey E.B., Goudreau J.L. & Schott H.C. 2020. Restoring *pars intermedia* dopamine concentrations and tyrosine hydroxylase expression levels with pergolide: evidence from horses with pituitary *pars intermedia* dysfunction. BMC Vet. Res. 16:356. <https://dx.doi.org/10.1186/s12917-020-02565-3>
- Hautala K., Näreaho A., Kauppinen O., Nielsen M.K., Sukura A. & Rajala-Schultz P.J. 2019. Risk factors for equine intestinal parasite infections and reduced efficacy of pyrantel embonate against *Parascaris* sp. Vet. Parasitol. 273:52-59. <https://dx.doi.org/10.1016/j.vetpar.2019.08.004> <PMid:31442894>
- Henker L.C., Bandinelli M.B., Andrade C.P., Bianchi M.V., Sonne L., Driemeier D., Soares J.F. & Pavarini S.P. 2020. Pathological, immunohistochemical, and molecular findings of equine protozoal myeloencephalitis due to *Sarcocystis neurona* infection in Brazilian horses. Trop. Anim. Health Prod. 52(6):3809-3817. <https://dx.doi.org/10.1007/s11250-020-02419-y> <PMid:33011934>
- Ireland J.L. & McGowan C.M. 2018. Epidemiology of pituitary *pars intermedia* dysfunction: A systematic literature review of clinical presentation, disease prevalence and risk factors. Vet. J. 235(1):22-33. <https://dx.doi.org/10.1016/j.tvjl.2018.03.002> <PMid:29704935>
- Jorgensen A.J.R., Donaldson M.T. & Habecker P.L. 2005. Development of equine protozoal myeloencephalitis in a horse with a clinically inapparent, functional pituitary *pars intermedia* adenoma (equine Cushing's disease). Equine Vet. Educ. 17(4):179-186. <https://dx.doi.org/10.1111/j.2042-3292.2005.tb00365.x>
- Leitenbacher J. & Herbach N. 2016. Age-related qualitative histological and quantitative stereological changes in the equine pituitary. J. Comp. Pathol. 154(2/3):215-224. <https://dx.doi.org/10.1016/j.jcpa.2015.11.006> <PMid:26810844>
- McFarlane D. 2011. Equine pituitary *pars intermedia* dysfunction. Vet. Clin. N. Am., Equine Pract. 27(1):93-113. <https://dx.doi.org/10.1016/j.cveq.2010.12.007> <PMid:21392656>
- McFarlane D., Donaldson M.T., Saleh T.M. & Cribb A.E. 2003. The role of dopaminergic neurodegeneration in equine pituitary *pars intermedia* dysfunction (equine Cushing's disease). Proc. Am. Assoc. Equine Pract. 49(1):233-237.
- McGowan T.W., Pinchbeck G.P. & McGowan C.M. 2013. Prevalence, risk factors and clinical signs predictive for equine pituitary *pars intermedia* dysfunction in aged horses. Equine Vet. J. 45(1):74-79. <https://dx.doi.org/10.1111/j.2042-3306.2012.00578.x> <PMid:22594955>
- McKenzie E.C. 2007. Polyuria and polydipsia in horses. Vet. Clin. N. Am., Equine Pract. 23(3):641-653. <https://dx.doi.org/10.1016/j.cveq.2007.08.001> <PMid:18061855>
- Miller M.A. 2017. Endocrine system, p.682-723. In: Zachary J.F. (Ed.), Pathologic Basis of Veterinary Disease. 6th ed. Elsevier, St. Louis.
- Miller M.A., Moore G.E., Bertin F.R. & Kritchevsky J.E. 2016. What is new in old horses? *Post-mortem* diagnoses in mature and aged equids. Vet. Pathol. 53(2):390-398. <https://dx.doi.org/10.1177/0300985815608674> <PMid:26459516>
- Millington W.R., Dybal N.O., Dawson Jr R., Manzini C. & Mueller G.P. 1988. Equine Cushing's disease: differential regulation of  $\beta$ -endorphin processing in tumors of the intermediate pituitary. Endocrinology 123(3):1598-1604. <https://dx.doi.org/10.1210/endo-123-3-1598> <PMid:2456916>
- Morgan R.A., Keen J.A., Homer N., Nixon M., McKinnon-Garvin A.M., Moses-Williams J.A., Davis S.R., Hadoke P.W.F. & Walker B.R. 2018. Dysregulation of cortisol metabolism in equine pituitary *pars intermedia* dysfunction. Endocrinology 159(11):3791-3800. <https://dx.doi.org/10.1210/en.2018-00726> <PMid:30289445>
- Paus R., Maurer M., Slominski A. & Czarnetzki B.M. 1994. Mast cell involvement in murine hair growth. Develop. Biol. 163(1):230-240. <https://dx.doi.org/10.1006/dbio.1994.1139> <PMid:8174779>
- Robson P.J., Alston T.D. & Myburgh K.H. 2003. Prolonged suppression of the innate immune system in the horse following an 80 km endurance race. Equine Vet. J. 35(2):133-137. <https://dx.doi.org/10.2746/042516403776114144> <PMid:12638788>
- Rohrbach B.W., Stafford J.R., Clermont R.S.W., Reed S.M., Schott II H.C. & Andrews F.M. 2012. Diagnostic frequency, response to therapy, and long-term prognosis among horses and ponies with pituitary *pars intermedia* dysfunction, 1993-2004. J. Vet. Intern. Med. 26(4):1027-1034. <https://dx.doi.org/10.1111/j.1939-1676.2012.00932.x> <PMid:22524260>
- Rose J. 1998. Adrenocorticotrophic hormone (ACTH) but not alpha-melanocyte stimulating hormone ( $\alpha$ -MSH) as a mediator of adrenalectomy induced hair growth in mink. J. Invest. Dermatol. 110(4):456-457. <https://dx.doi.org/10.1046/j.1523-1747.1998.00142.x> <PMid:9540992>
- Rosol T.J. & Gröne A. 2016. Endocrine glands, p.269-357. In: Maxie M.G. (Ed.), Jubb, Kennedy, and Palmer's Pathology of Domestic Animals. Vol.3. 6th ed. Elsevier, St. Louis. <https://dx.doi.org/10.1016/B978-0-7020-5319-1.00014-1>
- Rosol T.J. & Meuten D.J. 2017. Tumors of the endocrine glands, p.766-833. In: Meuten D.J. (Ed.), Tumors in Domestic Animals. 5th ed. John Wiley and Sons, Ames. <https://dx.doi.org/10.1002/9781119181200.ch18>
- Schott H.C. 2002. Pituitary *pars intermedia* dysfunction: equine Cushing's disease. Vet. Clin. N., Am. Equine Pract. 18(2):237-270. <https://dx.doi.org/10.1016/S0749-0739(02)00018-4> <PMid:15635907>
- Spelta C.W. 2015. Equine pituitary *pars intermedia* dysfunction: current perspectives on diagnosis and management. Vet. Med., Auckland, 6:293-300. <https://dx.doi.org/10.2147/VMRR.S74191> <PMid:30101114>
- Timper K. & Brüning J.C. 2017. Hypothalamic circuits regulating appetite and energy homeostasis: pathways to obesity. Dis. Model. Mech. 10(6):679-689. <https://dx.doi.org/10.1242/dmm.026609> <PMid:28592656>
- Welsh C.E., Duz M., Parkin T.D.H. & Marshall J.F. 2016. Prevalence, survival analysis and multimorbidity of chronic diseases in the general veterinarian-attended horse population of the UK. Prev. Vet. Med. 131:137-145. <https://dx.doi.org/10.1016/j.prevetmed.2016.07.011> <PMid:27544263>
- Zak A., Siwinska N., Elzinga S., Barker V.D., Stefaniak T., Schanbacher B.J., Place N.J., Niedzwiedz A. & Adams A.A. 2020. Effects of advanced age and pituitary *pars intermedia* dysfunction on components of the acute phase reaction in horses. Domest. Anim. Endocrinol. 72:106476. <https://dx.doi.org/10.1016/j.domaniend.2020.106476> <PMid:32380311>