



Retrospective study of fractures in the white-eared opossum (*Didelphis albiventris*) from 2020 to 2024

Juliana P. Tribucci², Letícia R. Inamassu³, Maria Jaqueline Mamprim³,
Tais Harumi C. Sasahara³, Bruno Cesar Schimming^{3*}

ABSTRACT. Tribucci JP, Inamassu LR, Mamprim MJ, Sasahara THC, Schimming BC. **Retrospective study of fractures in the white-eared opossum (*Didelphis albiventris*) from 2020 to 2024.** *Pesquisa Veterinária Brasileira* 46:e07736, 2026. Departamento de Anatomia, Universidade Estadual Paulista “Júlio de Mesquita Filho”, Cx. Postal 510, Botucatu, SP 18618-970, Brazil. E-mail: bruno.schimming@unesp.br

Fractures are a major problem in opossums found in urban environments, and knowledge of fracture location is of great importance for the success of veterinary care for this marsupial, aiming for successful healing. Due to the proximity of urban centers to forested areas, contact between humans and wildlife, especially marsupials, is increasingly intense. Therefore, wild animals, such as the white-eared opossum, are increasingly treated at veterinary centers. Thus, the objective of this study was to report the case series of fractures of this marsupial species treated and radiographed at the Veterinary Hospital, School of Veterinary Medicine and Animal Science, São Paulo State University (Unesp), Botucatu Campus, from 2020 to 2024. This analysis showed that of the 93 animals registered during this period, 38 (40.8%) presented fractures, with 44.7% occurring during the spring. The study also shows that the main cause of the fractures was dog attacks, accounting for 15 cases (39.4%). Regarding anatomical location, out of a total of 88 fractures, the most affected bone group was the vertebral column with 15 fractures (17%), followed by the ribs and mandible, each with 14 fractures (16%). Based on the results of this study, it is suggested that during this retrospective study period, the number of fractures in white-eared opossums was higher in the spring due to dog attacks, which resulted in rib fractures. Given this data, further research into mitigation strategies to decrease the risk of fractures should be considered.

INDEX TERMS: Fracture, marsupial, white-eared opossum, wildlife.

RESUMO.- [Estudo retrospectivo de radiografias com fraturas em gambás-de-orelha-branca de 2020 a 2024].

As fraturas são um grande problema em gambás encontrados em ambientes urbanos e o conhecimento do local da fratura é de grande importância para o sucesso do atendimento veterinário deste marsupial objetivando o sucesso da cura. Devido à proximidade dos centros urbanos com as áreas florestais, o contato entre seres humanos e a fauna silvestre, especialmente os marsupiais, é cada vez mais intensificado. Visto isso, animais selvagens como o gambá-de-orelha-branca são, cada vez mais, atendidos nos centros veterinários. Assim, o objetivo deste estudo foi relatar a casuística de fraturas dessa

espécie de marsupial atendida e radiografada no Hospital Veterinário, Faculdade de Medicina Veterinária e Zootecnia (FMVZ), Universidade Estadual Paulista “Júlio de Mesquita Filho” (Unesp), Campus de Botucatu, de 2020 a 2024. Essa análise evidenciou que de 93 animais cadastrados nesse período, 38 apresentavam fraturas (40,8%), sendo 44,7% dos casos ocorridos durante a primavera. O estudo demonstra também que a principal origem das fraturas foi ataque de cão, 15 casos (39,4%). Em relação à localização anatômica, de um total de 88 pontos fraturados, o conjunto de ossos mais acometido foi a coluna vertebral com 15 fraturas (17%), seguido pelas costelas e mandíbula, cada um com 14 fraturas (16%). Com base nos achados deste estudo, sugere-se que, no período deste estudo retrospectivo, a casuística das fraturas em gambás-de-orelha-branca foi maior na primavera devido a ataques de cães, que resultaram em fraturas nas costelas. Diante desses dados, pesquisas adicionais sobre estratégias de mitigação para diminuir o risco de fraturas devem ser consideradas.

TERMOS DE INDEXAÇÃO: Fraturas, gambá-de-orelha-branca, marsupial, animais selvagens.

¹ Received on August 26, 2025.

Accepted for publication on November 4, 2025.

² Undergraduate student in Veterinary Medicine, Faculdade de Medicina Veterinária e Zootecnia (FMVZ), Universidade Estadual Paulista “Júlio de Mesquita Filho” (Unesp), Botucatu, SP 18618-681, Brazil.

³ Graduate Program in Wild Animals, Faculdade de Medicina Veterinária e Zootecnia (FMVZ), Universidade Estadual Paulista “Júlio de Mesquita Filho” (Unesp), Botucatu, SP 18618-681, Brazil. *Corresponding author: bruno.schimming@unesp.br

INTRODUCTION

Marsupials are an important class of mammals found in the Americas and Australia, and include several species such as kangaroos, koalas, and opossums (Nowak 2005). Opossums belong to the family Didelphidae and the genus *Didelphis*. Although they prefer humid, tropical environments, they can adapt to various environments; thus, this genus has a wide geographic distribution throughout the Americas (Flórez-Oliveros & Vivas-Serna 2020). In Brazil, there is a wide variety of Didelphidae species, such as *Didelphis albiventris*, *Didelphis aurita*, *Didelphis imperfecta*, and *Didelphis marsupialis*, distributed throughout the country (Tardieu et al. 2017).

The white-eared opossum (*D. albiventris*) is characterized primarily by its white ears with a black base and, in addition, has grayish fur all over its body that becomes black at the extremities. Also on its head, there are bands of black hair around the eyes and on the rostral portion of the face, whose end approaches the pink snout (Flórez-Oliveros & Vivas-Serna 2020). They are nocturnal animals (Smith 2007) and exhibit solitary and territorial behaviors regarding their home range (Nowak 2005). They are agile on flat terrain, but somewhat slower in trees (Smith 2007) and use their prehensile tail as a fifth limb (Massoia et al. 2000).

The locomotor system is essential for the survival of wild animals, including the white-eared opossum. The ability to move is closely related to meeting basic needs and the manifestation of natural behaviors, such as feeding, escape, and reproduction. Accidents and traumas, whether anthropogenic or not, that affect the locomotor system of these animals can pose risks to their survival (Henning et al. 2015).

Regarding marsupial mammals, there are previous studies on the origins and outcomes of fractures in koalas, such as the study performed by Henning et al. (2015). To the best of the authors' knowledge, no retrospective study has yet been described about fractures in white-eared opossums, although, unfortunately, this neotropical marsupial is among the most frequently affected mammals by road mortality in São Paulo and Brazil (Abra et al. 2021, Pinto et al. 2022). Therefore, studying the origins and types of fractures in these marsupials and their relationships to behavioral characteristics can contribute to a better understanding of the outcomes of treatment performed on these animals. According to Henning et al. (2015), the study of fracture origins, for example, is essential to the success of both the healing process and the release of these animals and may aid veterinarians in the clinical management of these marsupials. Thus, the aim of this study was to analyze fractures in white-eared opossums through a retrospective analysis of data from the Veterinary Hospital, "Faculdade de Medicina Veterinária e Zootecnia" (School of Veterinary Medicine and Animal Science - FMVZ), Universidade Estadual Paulista "Júlio de Mesquita Filho" (Unesp), Botucatu, São Paulo.

MATERIALS AND METHODS

Ethical approval. This study was approved by the Institutional Committee on the Use of Animals (CEUA 7380270922).

Databases covering the period 2020 to 2024 were used for white-eared opossums (*Didelphis albiventris*) treated for fractures and/or dislocations at the Veterinary Hospital of the FMVZ-Unesp, Botucatu, São Paulo. Only opossums that were radiographed were included

in this study. The fracture data were obtained through analysis of radiographic images as well as the reports of the respective images, both present in the Veterinary Hospital's system.

The information includes, when available, sex, season when the fracture occurred (summer, fall, winter, or spring), the cause of the trauma that caused the fracture, and outcome (medical discharge, death, euthanasia, placement, or release). In this study, it was not possible to estimate the animals' ages, as this information was not included in the registration form. Radiographic examination identified the location of the fracture, the affected bone, and the presence or absence of bone splinters and dislocations. A few radiographs were not diagnostic; however, all radiographs were re-evaluated. Once the data was obtained, spreadsheets were created, from which the averages and percentages were determined. Descriptive analysis was conducted on the data obtained.

RESULTS

A total of 93 white-eared opossums (*Didelphis albiventris*) were admitted to the Veterinary Hospital, FMVZ-Unesp, Botucatu, from January 2020 to December 2024. Of these animals, 40 were males, 18 were females, and 35 did not have their sex identified. Of the total number of admitted animals, 38 (40.8%) presented at least one fracture, either in the axial or appendicular skeleton. A total of 20 (52.6%) of opossums admitted with fractures were male, nine (23.7%) were female, and nine (23.7%) did not have their sex identified.

Regarding the period of occurrence of fractures, eight (21%) occurred in 2020, zero (0%) in 2021, 12 (31.6%) in 2022, seven (18.4%) in 2023, and eleven (28.9%) in 2024. Regarding the seasonal pattern of fracture admissions (number of submissions per season across all years), 17 animals were admitted in spring (44.7%), eleven in winter (28.9%), eight in autumn (21%) and two in summer (0.05%) (Fig. 1).

Considering all 38 fractured animals, there were 44 fractured bones, 12 (27.3%) in the vertebral column, 10 (22.7%) in the skull, 10 (22.7%) in the pelvic limb, and four (9%) in the thoracic limb. The greater number of fractures relative to the number of animals is because some animals presented more than one fracture. It is noteworthy that, in this study, no fractures were observed in the epipubic bones. In this total of fractures, 88 fractured points were observed, with the most recurrent cases being: 15 (17%) in the vertebral column, 14 (16%) in ribs, and 14 (16%) in the jaw (Fig. 2-4). Therefore, in this study, the most affected

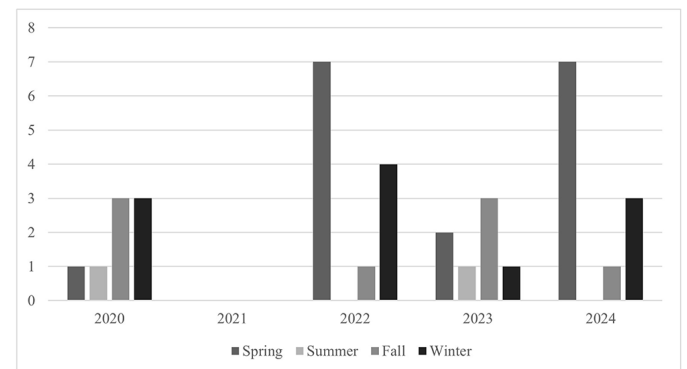


Fig. 1. Number of white-eared opossums admitted from 2020 to 2024 by season (spring, summer, autumn, and winter).

anatomical site by fractures was the vertebral column, with two (2.3%) fractures in thoracic vertebrae, nine (10.2%) in lumbar vertebrae, two (2.3%) in sacral vertebrae, and two (2.3%) in caudal vertebrae. In this study, no fractures were observed in cervical vertebrae. The ribs and the mandible were the second most affected anatomical sites by fractures in the white-eared opossums. Regarding the opossum ribs, the fractures were observed mainly in the eighth, ninth, and tenth ribs. The mandible was the third most affected anatomical site

by fractures, with 14 (16%) fractures. Moreover, the opossum skull presented fractures in other anatomical locations, such as the zygomatic bone with 10 fractures (11%), the frontal bone with two fractures (2%), and the temporal and maxilla bones with one fracture each (1% each) (Fig. 5).

In this study, considering a total of 38 opossums with fractures, one fracture was observed in 14 animals, two fractures in nine animals, three fractures in seven animals, four fractures in five animals, and five fractures in three animals.

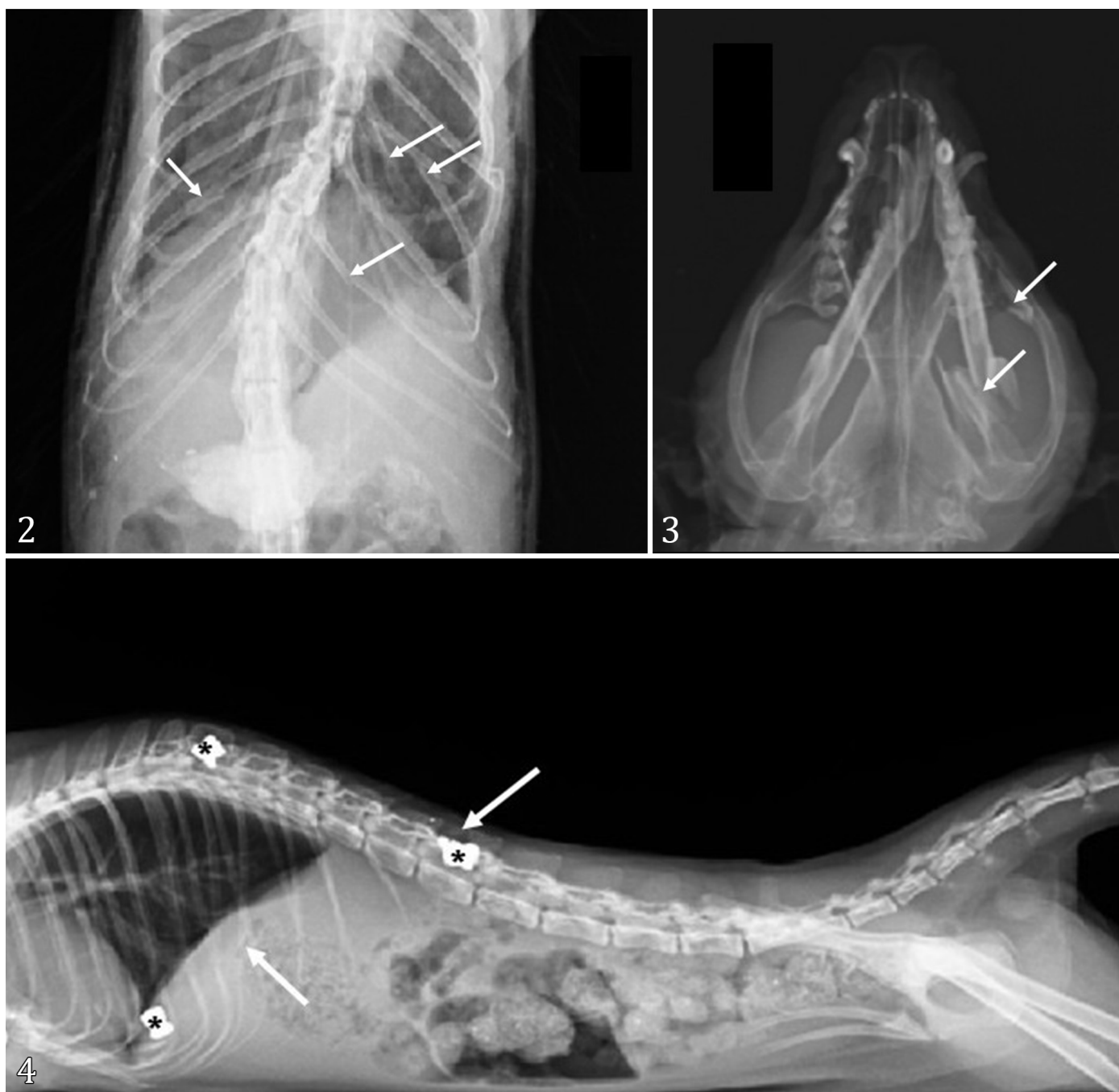


Fig. 2-4. Radiographic images. (2) Ventro-dorsal projection, showing multiple fractures (arrows) in the ribs. (3) Ventro-dorsal projection, showing fractures (arrows) in the left zygomatic arch, caudal third of the left mandibular body and the coronoid process of the left mandible. (4) Latero-lateral projection, showing ballistic artifacts (asterisks) with fractures in the second lumbar vertebra (arrow) and ribs (arrow).

It is also noteworthy that of the total of 88 fractures, 87 were closed fractures and one was an open fracture, which occurred in the femur. Regarding complete and incomplete fractures, 79 complete fractures were observed, with 75 being simple fractures (31 transverse and 44 oblique) and four comminuted fractures. In addition, nine fractures were incomplete, with three being concave and six convex.

Regarding the fractures observed in the white-eared opossum limbs, six fractures were observed in the thoracic limb: two fractures in the middle third of the humerus diaphysis, two fractures in the middle third of the radius diaphysis, and two fractures in the middle third of the ulna diaphysis. Animals with radius fractures also had concomitant ulna fractures. Twenty-five fractures were observed in the pelvic limb, including six fractures in the ilium, six fractures in the ischium, one fracture in the pubis, nine fractures in the femur (two fractures in the femoral neck, two in the femoral head, five in the femoral diaphysis with four fractures in the proximal third of the diaphysis and one fracture in the distal third of the diaphysis), one fracture in the proximal third of the tibial diaphysis and two fractures in the proximal third of the fibular diaphysis.

Regarding the presence of bone splinters and dislocations, it is noted that the former are observed in six of the 38 (15.8%) cases, while the latter are observed in 20 (52.6%).

It is noteworthy that no cases presented concomitant bone splinters and dislocations.

Table 1 shows the relationship between the possible causes of the fractures and the anatomical locations of the fractures. A total of 15 (39.5%) of fractures were caused by dog attacks, 11 (28.9%) were due to unknown causes, seven (18.4%) were caused by vehicle collisions, two (5.3%) were caused by falls, two (5.3%) had pathological fractures, that is, due to an inflammatory process and one (2.6%) was the victim of a human attack (2.6%).

Although we proposed considering the final evolution of the animals treated, this was not possible because the information was not included in the registration forms; therefore, it was not possible to relate the final evolution to the origin of the trauma and the fractured site. Of the 93 opossums registered, only nine had their final evolution reported on the registration forms, with six euthanasia, one release, and two deaths recorded. Regarding the euthanized animals, two were attacked by dogs (one animal with fractures in the ilium, pubis, and sixth and seventh lumbar vertebrae (L6 and L7); one animal with fractures in 13th thoracic vertebra (T13) and sixth, seventh, and ninth ribs), one had been run over (fracture in 13th thoracic vertebra T13), and two had unknown etiology (one with a fracture in the ilium and one without a fracture). The animal that was released after

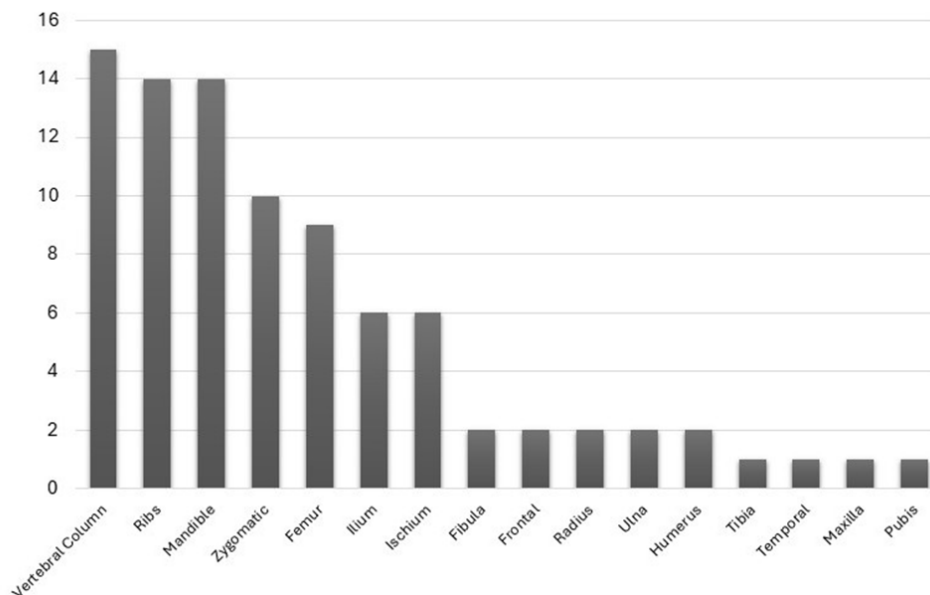


Fig. 5. Anatomical location of 88 fracture points observed in the white-eared opossums admitted from 2020 to 2024.

Table 1. Relationship between possible causes of the fractures and the anatomical locations of the fractures in the white-eared opossum

| Causes | Skull | Thoracic limb | Pelvic limb | Ribs | Vertebral column | Total |
|-----------------------|-------|---------------|-------------|------|------------------|-------|
| Dog attacks | 5 | 3 | 5 | 11 | 12 | 36 |
| Unknown | 4 | 3 | 12 | 3 | 0 | 22 |
| Vehicle collision | 8 | 0 | 7 | 0 | 3 | 18 |
| Inflammatory injuries | 3 | 0 | 1 | 0 | 0 | 4 |
| Falls | 3 | 0 | 0 | 0 | 0 | 3 |
| Human attacks | 5 | 0 | 0 | 0 | 0 | 5 |
| TOTAL | 28 | 6 | 25 | 14 | 15 | 88 |

treatment had no fractures and was admitted only with skin wounds, whereas of the animals that died, one was attacked by a dog (fractures in the eighth, ninth, and tenth ribs) and one was a victim of a human attack (fractures in the mandible and zygomatic bones).

DISCUSSION

The *Didelphis albiventris* has generalist and opportunistic habits, and these marsupials have great population density and ability to adapt to urban and peri-urban environments (Cáceres 2002, 2012, Flórez-Oliveros & Vivas-Serna 2020). However, the presence of opossums in urban habitats frequently results in elevated mortality rates, primarily due to anthropogenic factors such as road kills and fights with domestic dogs (Almeida et al. 2008). This study evaluates the database of white-eared opossums with fractures admitted to the Veterinary Hospital from 2020 to 2024. This Veterinary Hospital is in an area of two adjacent ecoregions: an Atlantic Forest-Cerrado interface. It is undeniable that the COVID-19 pandemic influenced the number of cases, as most cases brought to the Veterinary Hospital were rescues conducted by public agencies such as firefighters and environmental police, with the help of the local population. Thus, due to the lockdown and reduced number of workers, fewer animals may be rescued and taken for treatment. Despite the decrease in registered cases, especially in 2021, it is likely that there were fractures in white-eared opossums, since the main etiology recorded in other years was dog attacks rather than human attacks or being run over.

Moreover, the vulnerability of white-eared opossums to risks associated with human coexistence makes these marsupials victims of gunshot wounds (Gumier-Costa & Sperber 2009, Timóteo et al. 2025), dog attacks and roadkills (Abra et al. 2021, Pinto et al. 2022). In this study, the most common causes of fractures were dog attacks and vehicle collisions, although there were also unknown causes, falls, and human attacks. These findings are consistent with those reported for other marsupials, such as the koala, although vehicle collisions were the main cause of fractures in koalas (Henning et al. 2015). Behavioral differences between opossums and koalas could explain the difference in the main cause of fractures between these two marsupials, since opossums are omnivorous. They can invade a home in search of food, making them more susceptible to attack by dogs. In contrast, koalas are solitary arboreal folivores that specialize in a nutrient-poor diet of eucalyptus leaves and reside in the eucalyptus forests and semi-open woodlands of eastern Australia, as well as on coastal islands (Ellis et al. 2009). Pinto et al. (2015) reported that the white-eared opossum (*D. albiventris*) showed the highest mean estimated roadkill rate. To these authors, roadkill poses serious risks to mammal conservation in Brazil. Moreover, unfortunately, human attacks on opossums are not rare. A previous study identified 10 gunshot bullets in the white-eared opossum, seven in the head region and one in the foot (Timóteo et al. 2025). The causes of the fractures found in this study (dog attacks, vehicle collisions, human attacks, etc.) probably contribute to the increase in mortality rates, including traumatic injuries due to environmental anthropization and because the white-eared opossum adapts and lives in the anthropized environment.

In this study, more fractures (52.6%) were found in male white-eared opossums, which is similar to what was reported in a previous study for koalas, since 59.8% of the koalas submitted with fractures to the veterinary hospital in the South-East Queensland region (Australia) were males (Henning et al. 2015). Moreover, the peak period for traumatic injuries from 2020 to 2024 was observed in the spring season. The spring and summer comprise the warmer, rainy months in the region of this study, and spring marks the peak of the breeding season of white-eared opossums in southeastern Brazil (Cáceres 2000, Astúa & Geise 2006), the region where this study was carried out. We highlight the geographic region because, as the reproductive season is triggered by photoperiod, it can be observed in other periods depending on the Brazilian region (Astúa & Geise 2006). The findings of this study may be explained by higher activity among males than females, especially during the breeding season (spring), when testosterone levels increase, potentially exposing them to high-risk situations such as dog attacks and vehicle collisions.

The traumatic injuries appeared in the axial and appendicular bones of the white-eared opossum. This is consistent with a previous study carried out at the Veterinary Hospital of the "Universidade Federal Rural da Amazônia" (UFRA, Belém, Pará, Brazil) from 2013 to 2017, where 50% of all cases of wild mammals radiographed occurred in the locomotor apparatus of these animals (Jácomo et al. 2019). The vertebral column, ribs, and mandible were the most frequently affected anatomical locations by traumatic injuries in the white-eared opossum. The vertebral column was the most affected anatomical site by traumatic fractures, mainly in the lumbar vertebrae. Gusmão (2021), in a study of opossums treated and radiographed at the Veterinary Hospital of the "Universidade Federal do Rio Grande do Sul" (UFRGS, Porto Alegre, Rio Grande do Sul, Brazil) from 2015 to 2020, reported that most vertebrae affected by fractures were in the lumbar region of the vertebral column. Thus, this study agrees with Gusmão (2021) regarding the greater involvement of the lumbar vertebrae in relation to other parts of the vertebral column.

Dogs' attacks are more likely to involve the vertebrae, ribs and the trunk, which can be explained by the fragility of the vertebrae and ribs, and the possible canine predisposition to bite the abdominal and thoracic regions (Wong et al. 1999, Henning et al. 2015). Probably, this can explain the findings of this study regarding the vertebrae and ribs being the most affected anatomical sites and dog attacks being the main cause of traumatic injuries to the white-eared opossum. Moreover, Henning et al. (2015) reported that limb fractures may reflect the defense reaction of the mammal, as in human dog attack victims. The fractures observed in the hindlimb and forelimb bones of the white-eared opossum could be explained by this attitude of defending.

The white-eared skull was the third anatomical location of traumatic fractures. The mandible was the most frequently affected skull anatomical location by fractures. On the other hand, fractures observed in the opossums treated involved at least two skull bones, with the possibility of multiple concomitant fractures (Gusmão 2021). In contrast, in the study reported by Gusmão (2021), the skull was the most frequently fractured anatomical site in opossums. The findings of this study diverged from those of Gusmão (2021) regarding the most affected bones and from the latter's reports, which described

the zygomatic arch as the most fractured cranial site, since in our study, the most fractured bone in the opossum skull was the mandible - the zygomatic arch was the second most fractured bone. According to Henning et al. (2015), vehicle collisions are the cause of high numbers of head fractures, including skull and jaw fractures, followed by combination and limb fractures. This could explain the presence of jaw and zygomatic arch fractures in opossums, since vehicle collisions were among the causes of the fractures observed in this study. Moreover, dog attacks could involve mandible and zygomatic arch fractures (Wong et al. 1999).

CONCLUSION

The vertebral column had the most frequently fractured bones in white-eared opossums treated at the Veterinary Hospital of the FMVZ-Unesp, from January 2020 to December 2024. Regarding the etiology of fractures, dog attacks were the most common, and the highest incidence was observed in males treated in the spring. This retrospective study is important because knowledge of the most common types and variations of bone fractures in white-eared opossums can inform the clinical care of these marsupials and contribute to future studies in veterinary orthopedics, increasing the efficiency of treatment and rehabilitation of these animals, which increasingly live in urban environments.

Acknowledgments. The authors thank the Diagnostic Imaging Service, Veterinary Hospital, "Faculdade de Medicina Veterinária e Zootecnia", "Universidade Estadual Paulista 'Júlio de Mesquita Filho'" (Unesp), Botucatu, São Paulo, for allowing access to the data.

Conflict of interest statement- The authors have no conflict of interest.

Credit author statement. Bruno C. Schimming designed the study and revised the manuscript. Juliana P. Tribucci and Leticia R. Inamassu collected and analysed the data. Maria Jaqueline Mamprim and Tais H.C. Sasahara analysed the data. All authors helped to write the manuscript and read and approved the final manuscript.

Data availability statement. The data supporting this study are available and can be accessed upon request from the corresponding author.

Editor-in-Chief. Fabiano José Ferreira de Sant'Ana.

REFERENCES

- Abra FD, Huijser MP, Magioli M, Bovo AAA, Ferraz KMPMB. An estimate of wild mammal roadkill in São Paulo state, Brazil. *Heliyon* 2021; <https://doi.org/10.1016/j.heliyon.2021.e06015>
- Almeida AJ, Torquetti CG, Talamoni SA. Use of space by neotropical marsupial *Didelphis albiventris* (Didelphimorphia: Didelphidae) in an urban forest fragment. *Rev Bras Zool* 2008; <https://doi.org/10.1590/S0101-81752008000200008>
- Astúa D, Geise L. Early reproductive onset in the white-eared opossum, *Didelphis albiventris* Lund, 1840 (Didelphimorphia, Didelphidae). *Mamm Biol* 2006; <https://doi.org/10.1016/j.mambio.2006.03.003>
- Cáceres NC. Food habits and seed dispersal by the white-eared opossum, *Didelphis albiventris*, in Southern Brazil. *Stud Neotrop Fauna Environ* 2002; <https://doi.org/10.1076/snfe.37.2.97.8582>
- Cáceres NC. Os marsupiais do Brasil: biologia, ecologia e conservação. 2nd ed. Campo Grande: Ed. UFMS; 2012.
- Cáceres NC. Population ecology and reproduction of white-eared opossum *Didelphis albiventris* (Mammalia, Marsupialia) in an urban environment of Brazil. *Ciênc Cult* 2000; http://jararaca.ufsm.br/websites/niltoncaceres/download/Pop_ecol_2000.pdf
- Ellis WAH, Melzer A, Bercovitch FB. Spatiotemporal dynamics of habitat use by koalas: the checkerboard model. *Behav Ecol Sociobiol* 2009; <https://doi.org/10.1007/s00265-009-0761-2>
- Flórez-Oliveros FJ, Vivas-Serna C. Opossums (common chuchas), marmosas and colicortos in Colombia. Medellín: Fundación-Zarigüeya-Fundzar; 2020.
- Gumier-Costa F, Sperber CF. Atropelamentos de vertebrados na Floresta Nacional de Carajás, Pará, Brasil. *Acta Amazon* 2009; <https://doi.org/10.1590/S0044-59672009000200027>
- Gusmão CB. Achados radiográficos em mamíferos silvestres e exóticos atendidos pelo Hospital de Clínicas Veterinárias da UFRGS no período entre 2015 e 2020. TCC Graduação em Medicina Veterinária, 2021: Accessed on Jul 7, 2025. <http://hdl.handle.net/10183/271949>
- Henning J, Hannon C, McKinnon A, Larkin R, Allavena R. The causes and prognoses of different types of fractures in wild koalas submitted to wildlife hospitals. *Prev Vet Med* 2015; <https://doi.org/10.1016/j.prevetmed.2015.10.015>
- Jácomo AAF, Pereira THS, Matos SER, Leão AP, Faria BM, Silva AL, Santos RC, Ribeiro ASS. Levantamento dos exames radiográficos realizados em mamíferos selvagens e exóticos no hospital veterinário Mario Dias Teixeira: 2013 a 2017. *Rev Educ Contin Med Vet Zootec CRMV-SP* 2019; <https://shre.ink/qt01>
- Massoia E, Forasiepi A, Teta P. Los Marsupiales de la Argentina. Buenos Aires: L.O.L.A.; 2000. p.10-70.
- Nowak RM. Walker's Marsupials of the World. Baltimore: Johns Hopkins University Press; 2005.
- Pinto FAS, Cirino DW, Cerqueira RC, Rosa C, Freitas SR. How many mammals are killed on Brazilian roads? Assessing impacts and conservation implications. *Diversity* 2022; <https://doi.org/10.3390/d14100835>
- Smith P. White-Eared Opossum *Didelphis albiventris* (Lund, 1840). In: Smith P. *Didelphis albiventris* - Fauna Paraguay Handbook of the Mammals of Paraguay. Fauna Paraguay; 2007. p.1-19. (Number 1).
- Tardieu L, Adogwa AO, Garcia GW. *Didelphis* species, neo-tropical animals with the potential for intensive production: Part 1 review of taxonomy, natural history, general biology, animal behaviour, and nutrition. *Trop Agricult* 2017; <https://shre.ink/qt6e>
- Timóteo JL, Souza RHO, Campana NY, Morais JRC, Magajevski FS, Costa TD. Clinical evaluation and therapeutic management of traumatic injuries and complications in the white-eared opossums (*Didelphis albiventris*) - case report. *Arq Bras Med Vet Zootec* 2025; <https://doi.org/10.1590/1678-4162-13326>
- Wong JK, Blenkinsop B, Sweet J, Wood RE. A comparison of bite-mark injuries between fatal wolf and domestic dog attacks. *J Forensic Odontostomatol* 1999;17(1):10-15. PMID:10709557.